MOUNT SINAI-IRVING J. SELIKOFF CENTER FOR OCCUPATIONAL AND ENVIRONMENTAL MEDICINE

Occupational Asthma with Paroxysmal Atrial Fibrillation in a Diamond Polisher

Elizabeth Wilk-Rivard and Jaime Szeinuk

Mount Sinai-Irving J. Selikoff Center for Occupational and Environmental Medicine, Department of Community and Preventive Medicine, The Mount Sinai Medical Center, New York, New York, USA

We present a case of a diamond polisher who developed occupational asthma as a result of prolonged exposure to various potent and well-recognized asthma-inducing agents, including cobalt dust. Although the patient was seen by various medical professionals during the initial course of his illness and given an early diagnosis of a respiratory condition, there were no attempts to evaluate the nature of his work, and therefore to establish a possible causal relationship with his exposures. This case clearly illustrates the importance of such an assessment. The ultimate fate of this patient (he had to retire from his job with a chronic and permanent illness) could have been avoided by early environmental intervention. In addition, this case illustrates a possible complication of asthma, that is, a severe cardiac arrhythmia. In this case, both the patient's symptoms and the prescribed medications contributed to worsening of the patient's underlying condition. Early diagnosis and intervention of this patient's work practices could have avoided this complication.
***Key words*: cobalt, diamond polishing, metals, occupational asthma, paroxysmal atrial fibrillation, prevention. *Environ Health Perspect* 109:1303–1306 (2001). [Online 30 November 2001]**
http://ehpnet1.niehs.nih.gov/docs/2001/109p1303-1306wilk-rivard/abstract.html

Case Presentation

Initial clinical history. The patient, a 54-year-old man, was initially evaluated at the Mount Sinai-Irving J. Selikoff Center for Occupational and Environmental Medicine on 11 November 1999. He complained of shortness of breath, wheezing, chest tightness, dry cough, heart palpitations, and fatigue.

The patient had been a diamond grinder for 14 years. His medical history revealed breathing difficulties that began in 1996 and became progressively worse. The patient noticed that the onset of symptoms occurred at the end of his work shift or after returning home from work. He was free from symptoms during vacations and weekends.

In 1998 he developed heart palpitations that presented at the same time as his breathing difficulties. He underwent frequent hospitalizations and visits to the emergency department because of these sudden episodes of heart palpitations. Eventually these episodes were diagnosed as a paroxysmal atrial fibrillation.

Review of symptoms disclosed itching and burning of the eyes and itching of the skin related to his exposure at his work environment. These symptoms abated when the patient was away from his work.

His past medical history revealed frequent colds, mild sinusitis in 1998, and an appendectomy 20 years before his initial visit. He denied allergies to any medications or to any other substance and had never been diagnosed with asthma. He is a lifelong nonsmoker.

Previous clinical course. A diagnosis of "upper airway reactivity" was made in 1996, but the relationship to the patient's occupational exposure was not explored and no recommendations related to his work were ever made. The patient was later evaluated by a pulmonologist and a cardiologist, and given prescriptions for albuterol and fluticasone inhalers and for diltiazem and Coumadin.

The patient continued to work as a diamond grinder, with his illness becoming progressively worse. The frequency of his breathing difficulties and heart palpitations increased over time. He tried the inhalers but finally discontinued these medications because of his perception that they aggravated his heart palpitations.

The patient also discontinued diltiazem and Coumadin because he was very confused and anxious because he did not understand the nature of his disease.

Occupational history. The patient's major work task was to polish diamond-coated metal tools with a high-speed grinding disk coated with abrasive microdiamonds. He worked for 8 hr per day, 5 days per week. His workstation was equipped with a high-speed grinding disc covered with microdiamonds and was supplied with a local exhaust pipe located next to the grinding disc. The patient reported that the capacity of this pipe to extract the dust produced during grinding was very limited. He described his workplace as always being dusty. Residual dust could always be noticed around the exhaust pipe and over his workstation (Figure 1). The patient worked in a sitting position and was directly exposed to the dust from the grinding process. He sporadically wore a paper dust-mask as the only respiratory protection. Figures 1 and 2 show the patient's workstation and work tools. The patient supplied these photographs as per doctor's request in an attempt to provide more information about his occupational history.

Material safety data sheets of the patient's work revealed potential for exposure to the following substances: phenolic resins, teflon, calcium oxide, graphite, nickel, copper, silicon carbide, aluminum oxide, silver, chromium, magnesium oxide, tin, glass, cryolite, silica, iron, tungsten, tungsten carbide, phosphorus, and cobalt.

Physical examination. An initial physical examination at the Occupational Medicine Clinic revealed an elevated blood pressure of 145/90 mmHg and a regular heart rate of 82 beats/min. The patient's height was 6 feet and his weight was 200 pounds. There was moderate redness of the throat. Wheezing was noted over the upper part of the right lung. A linear appendectomy scar was noted in the right lower quadrant of the abdomen.

Address correspondence to J. Szeinuk, Department of Community and Preventive Medicine, The Mount Sinai Medical Center, Box 1057, 1 Gustave L. Levy Place, New York, NY 10029 USA. Telephone: (212) 241-4786. Fax: (212) 996-0407. E-mail: jaime.szeinuk@mssm.edu

We thank P.J. Landrigan and S.M. Levin for their correction of the manuscript. We also thank the reviewers for their contributions.

Received 17 July 2001; accepted 4 October 2001.

Subsequent physical examinations indicated irregular heart rhythm consistent with atrial fibrillation.

Laboratory evaluation. The patient had a complete blood count, blood chemistry, and urinalysis done in November 1999, for which all results were normal. A coronary arteriography and an echocardiogram performed in January 1997 were normal. A thallium stress test performed in December 1996 indicated reversible ischemic disease involving the septal wall of the left ventricle and irreversible ischemic disease of the inferior wall of the left ventricular myocardium. A chest radiograph was normal, and a chest computed tomography scan done on September 1998 indicated small pleural changes related to scarring.

Spirometry tests performed in 1998 and 1999 were normal. Diffusion capacity and arterial blood gases in March 1988 were normal as well.

Occupational medicine evaluation. Repeated chest X ray and repeated spirometry were normal.

The patient was asked to complete a peak expiratory flow (PEF) diary both at work and at home. The maximum PEF recorded was 800 mL, noted while the patient was free of symptoms, mostly at home or during weekends. The minimum PEF was 400 mL, recorded while the patient was experiencing breathing difficulties such as shortness of breath, dry cough, and wheezing, which happened most commonly at work or at home after the end of his shift. Figure 3 is a plot of the patient's PEF values against time. A methacholine challenge test was not performed because of the coexisting paroxysmal atrial fibrillation.

The pattern of PEF was consistent with a diagnosis of occupational asthma. There was a daily variability in PEF of > 20% between maximal and minimal values. There was a significant decrease in PEF while the patient worked with the grinding machine (shaded area in Figure 3) compared to days spent at work doing other tasks or compared to days off work.

Case management. The nature and implications of the diagnosis were explained to the patient. At the time of his visit to our clinic, improvement of the local exhaust system and building ventilation at patient's workplace was not possible. In addition, at that time he was unable to work with a respirator because of the severity of his symptoms. There was no other job available at his work site that did not include similar exposures. Therefore, we advised the patient to change his job. Because of economic constraints, however, he initially elected to continue to work; the patient reduced the number of hours he worked per week, but he continued to experience respiratory difficulties. He finally came to understand the work-related nature of his disease and became fully compliant with the prescribed treatment of bronchodilators and anticoagulants. He eventually decided to retire from his job.

Clinical follow-up. Subsequent clinical evaluations at our clinic after the patient had quit his job indicated improvement in asthma symptoms. In addition, the sudden episodes of paroxysmal atrial fibrillation were less frequent as well. The patient was compliant with his medication and continued to receive medical care by his pulmonologist and his cardiologist. A workers' compensation claim for occupational asthma was filed, and the patient was awarded compensation after his case was reviewed by a workers' compensation judge.

Discussion

Asthma of occupational origin accounts for 5–15% of all newly diagnosed cases of asthma (and up to 30% in some studies); it is the most common form of occupational lung disease in developed countries (*1,2*). Work-related asthma includes two categories: occupational asthma (OA) and work-aggravated asthma. OA is defined as asthma originating from causes and conditions attributable to a particular occupational environment and not related to stimuli outside of the workplace (*3,4*). Work-aggravated asthma is diagnosed in individuals with a history of asthma that is significantly worsened by workplace environmental exposure. Work-related asthma develops after occupational exposure to inhaled gases, dusts, fumes, or vapors.

Over 250 workplace chemicals have been etiologically related to OA. The initial clinical diagnosis is generally established based on a history of temporal association between exposure and the onset of symptoms (*1,3–5*). OA has been reported among hard metal workers exposed to low-molecular-weight metals such as cobalt, chromium, and nickel. Diamond polishers are one such group, and they develop asthma as a result of exposure to cobalt dust. The dust is generated from high-speed grinding disks coated with abrasive microdiamonds embedded in binding cobalt powder (*6–9*). In this paper, we describe the case of a diamond polisher who developed occupational asthma that was complicated by paroxysmal atrial fibrillation, a combination of diseases that placed the patient at a potential risk of embolic stroke (*10,11*).

Diagnosis of work-related asthma (*3*) involves establishing both the diagnosis of asthma and the relation between asthma and workplace exposures. The diagnostic process begins with a thorough medical and clinical evaluation, physical examination, and pulmonary function testing directed to confirm the diagnosis of asthma. Once this is confirmed, a complete occupational history is obtained. Specific points to outline in the occupational history are a pattern of temporal association between symptoms and workdays and a history of occupational exposure to symptom triggers, which may include either substances or practices at work. Objective information should be elicited as much as possible. Product information may be retrieved from review of labels or material safety data sheets. Comparing the listed components with published tables of agents known to be capable of producing occupational asthma is always recommended (*12–14*). Objective information about the workplace is better confirmed by a walk-through inspection of the workplace. The participation of industrial hygienists in this process is very helpful. Walk-throughs, however, require the cooperation from the employer, which is seldom attainable. If not available, further information of the workplace, such as drawings or photos of the area, are always helpful. Measurement of air concentrations of specific chemicals is not usually necessary in the evaluation of work-related asthma, as dose–response relationships are highly variable and extremely low or unmeasurable air concentrations can cause asthmatic



Figure 1. The patient's work station showing the high-speed grinding disc covered with microdiamonds and a local exhaust next to the grinding disc. Note the condition of the exhaust pipe next to the grinding disc.



Figure 2. Diamond-coated tools polished by the high-speed grinding disc in the work process.

responses (*3*). In everyday occupational clinical practice, qualitative exposure assessment is always more useful. This can be obtained by completing a diary of PEF measurements while at work and while away from work. Further information on the use and interpretation of PEF diaries in occupational asthma has been published elsewhere (*3,15*). Immunologic evaluation, either by skin prick testing or serologic titers, can be very helpful to confirm a diagnosis of occupational asthma, especially for sensitizing agents. Major limitations of these assays are the lack of standardization and the scarcity of those tests that have been adequately standardized. The use of the specific challenge test, although advocated by many as the "gold standard" in diagnosis of OA, is a very limited tool available only at few centers and has limitations on its own. In this patient's case, a diagnosis of OA was confirmed after carefully reviewing the occupational history, history of exposure, conditions of the workplace, and PEF diary.

The purpose of this case presentation is to demonstrate the importance of prompt recognition of occupational asthma, especially if the patient has additional health problems. In the early stage of his illness, this patient noticed only breathing difficulties. He was given a diagnosis of "upper airway reactivity." However, no connection was made to his workplace as a source of exposure to causative agents, although the patient's workplace material safety data sheets noted potential for exposure to chemicals such as nickel, chromium, phenolic resin, and cobalt, all known as capable of causing asthma. There was no assessment of the risk exposure in the workplace, and there was no early intervention or attempt to reduce or eliminate exposure. At the time of the initial evaluation, installation of engineering controls such as a proper exhaust ventilation system or containment of work processes could have prevented the development of permanent respiratory damage. If this was not possible, administrative controls such as modified duty or transfer to a different work task should have been recommended to reduce work exposure. In addition, advice to wear a proper respirator while working could have decreased the patient's exposure. Some authors have described asthmatic patients who were able to return to work with the help of appropriate respirators, even when exposed to sensitizing agents (*16*). There was, however, nothing done at an early stage to fully recognize and diminish this patient's work exposure. At the time of his evaluation at the occupational clinic, the history of aggravation of his symptoms despite treatment, his significant anxiety resulting from lack of response, and his awareness as to the nature and cause of his disease, combined with his inabilities to control his occupational exposure and to wear a respirator, prompted us to recommend removal from his work. The fact that, initially, the patient's symptoms significantly decreased during weekends and vacations could have signified a better chance for improvement of his disease (*5*). This opportunity, however, was lost because of the delay of the diagnosis of occupational asthma and the delay of proper intervention in the work environment.

This case further describes the difficulty of managing occupational asthma when it is not possible to change conditions in the workplace. The progression of underrecognized occupational asthma to chronic and permanent disability is a well-recognized fact in the occupational medical literature (*3,17,18*). When faced with the impossibility of establishing controls at the workplace or the lack of response to engineering or administrative controls and use of personal protective equipment, the only reasonable recommendation left for the treating physician to make is to ask the patient to leave his job. Most authors agree that the treatment of sensitizer-induced OA is removal from exposure (*17*). Vocational retraining should be always considered in these cases.

This case is a good example of the public health implications of a diagnosis of occupational asthma. A patient who has been diagnosed with OA should be considered a sentinel case, and it is the responsibility of the treating physician to discover and prevent new episodes of disease in co-workers. There are different strategies in implementing public health awareness and corrective measurements at the workplace. More details of this important issue have been published by Friedman-Jimenez et al. (*3*).

After 2 years of breathing difficulties related to occupational asthma, this patient developed paroxysmal atrial fibrillation. The incidence of atrial fibrillation increases with age, coronary disease, hypertension, valvular heart disease, and hypertrophic cardiomyopathy (*19–21*). Atrial fibrillation is a significant risk factor for nonembolic stroke [relative risk (RR) = 1.56], embolic stroke (RR = 5.8), and mortality (RR = 1.31) (*22*). Because of the excessive risk of stroke, the patient was treated with Coumadin, an anticoagulant medication known to reduce the risk of stroke (*22*).

This patient reported an association of his symptoms of occupational asthma while at work with the presence of palpitations. It is difficult to ascertain a causal relationship between the worsening of cardiac symptoms and this patient's asthma. In patients with obstructive lung disease and cardiac arrhythmia, bronchodilating agents such as beta-receptor agonists or theophylline preparations have been reported to induce supraventricular tachyarrhythmias (*23,24*). This patient, however, was treated with relatively lung-selective bronchodilators, which would be expected to be less likely to induce arrhythmia. There is also epidemiologic evidence that patients with severe asthma have increased mortality from ischemic heart disease (*25*). In any event, the association of arrhythmia and asthma resulted in a significantly increased morbidity that caused him to repeatedly consult the emergency room for heart palpitations. In addition, this association made the patient's asthma treatment much more difficult. As noted, lack of early recognition of the origin of this patient's asthma resulted in progressive aggravation of this illness, which contributed to aggravating and further complicating the general management of his cardiac and pulmonary conditions.

Occupational exposure in this patient included exposure to cobalt dust. Exposure to cobalt has been historically linked to the

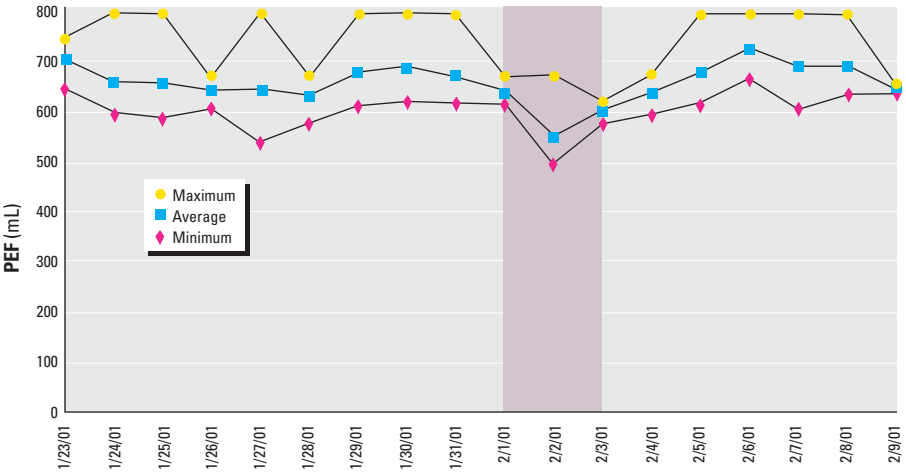

Figure 3. The plot of the patient's PEF values diary. The shaded area indicates the period that the patient worked with the grinding machine during the occupational evaluation.

development of cardiomyopathy after an epidemic of this disease was described in a group of heavy drinkers of beer to which cobalt sulfate had been added as a foam stabilizer (*26*). A major pathologic finding in patients from this group who died was myocardial necrosis with thrombi in the heart and major blood vessels. Other clinical features included polycythemia, pericardial effusion, and thyroid hyperplasia. Cobalt depresses oxygen uptake by the mitochondria of the heart and interferes with energy metabolism in a manner similar to the effects of thiamin deficiency, which explained the pathophysiology of cardiomyopathy in these patients. In the present patient, extensive cardiac evaluation, which included electrocardiogram, echocardiogram, stress test, and coronary arteriography, ruled out any evidence of cardiomyopathy. This led us to dismiss this diagnosis as a possible explanation for this patient's symptoms and clinical findings.

Biologic monitoring for cobalt exposure using blood or urine samples has been performed in studies of cobalt exposure. Urine excretion of inhaled cobalt has a two-phase kinetics that does not allow easy correlation between end-shift urinary and ambient air levels. Therefore, demonstration of cobalt in body fluids may not be useful in identifying risk for asthma, and as such it was considered not useful in diagnosing and managing this patient (*27*).

In summary, we have presented a case of a diamond-polisher who developed occupational asthma as a result of prolonged exposure to many potent and well-recognized asthma-inducing agents, of which the most probable cause was cobalt dust. Although the patient was seen by various medical professionals during the initial course of his illness and given an early diagnosis of a respiratory condition, attempts to evaluate the nature of his work and therefore to establish a possible causal relationship with his exposures were not undertaken. The occupational and general medical literature increasingly cautions medical professionals to strongly consider the possibility of occupational asthma in any new-onset asthma in an adult patient (*28*). This case clearly illustrates the importance of such an assessment. The ultimate fate of this patient—having to retire from his job with a chronic and permanent illness—could have been avoided by early environmental intervention (*5*). This case also illustrates a not-so-frequent complication of asthma: the association with a severe cardiac arrhythmia. In this case, both the patient's symptoms and the medications contributed to the worsening of this patient's underlying condition. Early diagnosis and intervention of this patient's work practices could have avoided this complication.

References and Notes

1. Beckett WS. Occupational respiratory diseases. N Engl J Med 342:406–413 (2000).
2. Johnson AR, Dimich-Ward HD, Manfreda J, Becklake MR, Ernst P, Sears MR, Bowie DM, Sweet L, Chang-Yeung M. Occupational asthma in adults in six Canadian communities. Am J Respir Crit Care Med 162:2058–2062 (2000).
3. Friedman-Jimenez G, Beckett WS, Szeinuk J, Petsonk EL. Clinical evaluation, management, and prevention of work-related asthma. Am J Ind Med 37:121–141 (2000).
4. Lombardo LJ, Balmes JR. Occupational asthma: a review. Environ Health Perspect 108(suppl 4):697–704 (2000).
5. de la Hoz RE, Rom WN. Clinical diagnosis of occupational versus work-aggravated asthma. Reprint Can J Clin Med 5:2–7 (1998).
6. Lizarralde SM, Wake B, Thompson V, Weisman R. Jewelers. In: Occupational, Industrial, and Environmental Toxicology (Greenberg MI, Hamilton RJ, Phillips SD, eds). 1st ed. St. Louis, MO:Year Book Inc., 1997;153–170.
7. Suardi R, Belloti L, Ferrari MT, Leghissa P, Caironi M, Maggi L, Alborghetti F, Storto T, Silva T, Piazzolla S. Health survey of workers occupationally exposed to cobalt. Sci Total Environ 150:197–200 (1994).
8. Van den Eckhout AV, Verbeken E, Demedts M. Pulmonary pathology due to cobalt and hard metals. Rev Mal Respir 6:201–207 (1989).
9. Kusaka Y, Ichikawa Y, Sugimoto K, Goto S. Bronchopulmonary diseases due to ultra-hard metal dust, with special reference to the result of the dust analysis. Sangyo Igaku 25:155–160 (1983).
10. Hylek EM, Skates SJ, Sheehan MA, Singer DE. An analysis of the lowest effective intensity of prophylactic anticoagulation for patients with non-rheumatic atrial fibrillation. N Engl J Med 335:540–546 (1996).
11. Gaughan GL, Dolan C, Wilk-Rivard E, Geary G, Libbey R, Gilman MA, Lanata H. Improving management of atrial fibrillation and anticoagulation in a community hospital. Jt Comm J Qual Improv 26:18–28 (2000).
12. Chan-Yeung M, Malo JL. Aetiological agents in occupational asthma. Eur Respir J 7:346–371 (1994).
13. Malo JL, Cartie A. Appendix B: Key references in occupational asthma. In: Occupational and Environmental Respiratory Disease (Harber P, Schenker M, Balmes J, eds). 1st ed. St.Louis, MO:Mosby, 1996;1006–1022.
14. Van Kampen V, Merget R, Baur X. Occupational airway sensitizers: an overview of the respective literature. Am J Ind Med 38:164–218 (2000).
15. Gannon PFG, Burge PS. Serial peak expiratory flow measurement in the diagnosis of occupational asthma. Eur Respir J Suppl 24:57S–63S (1997).
16. Obase Y, Shimoda T, Mitsuta K, Matsuse H, Kohno S. Two patients with occupational asthma who returned to work with the dust respirators. Occup Environ Med 57:62–64 (2000).
17. Chan-Yeung M, Malo JL. Occupational asthma. N Engl J Med 333:107–112 (1995).
18. Cannon J, Cullinan P, Newman Taylor A. Consequences of occupational asthma. Br Med J 311:602–603 (1995).
19. Ostfeld AM, Wilk E. Epidemiology of stroke, 1980–1990: a progress report. Epidemiol Rev 12:253–256 (1990).
20. Bhatia A, Sra J. Atrial fibrillation: epidemiology, mechanism and management. Indian Heart J 52:129–164 (2000).
21. Olivotto I, Maron BJ, Cecchi F. Clinical significance of atrial fibrillation in hypertrophic cardiomyopathy. Curr Cardiol Rep 3:141–146 (2001).
22. Yuan Z, Bowlin S, Einstadter D, Cebul RD, Conners AR, Rimm AA. Atrial fibrillation as a risk for stroke; a retrospective cohort study of hospitalized Medicare beneficiaries. Am J Public Health 88:395–400 (1988).
23. Lim R, Walshaw MJ, Saltissi S. Hind CR. Cardiac arrhythmias during acute exacerbations of chronic airflow limitation: effect of fall in plasma potassium concentration induced by nebulised beta 2-agonist therapy. Postgrad Med J 65:449–452 (1989).
24. Ohtake H, Misaki T, Matsunaga Y, Tubota M, Kawasuji M, Wantanabe Y. Surgical therapy for Wolff-Parkinson-White syndrome in patients with bronchial asthma. Cardiovasc Surg 1:53–56 (1996).
25. Toren K, Lindhom NB. Do patients with severe asthma run an increased from ischaemic heart disease? Int J Epidemiol 25:617–620 (1996).
26. Jarvis JQ, Hammond E, Meier R, Robinson C. Cobalt cardiomyopathy. A report of two cases from mineral assay laboratories and a review of the literature. J Occup Med 34:620–626 (1992).
27. Kreiss K. Cobalt. In: Textbook of Clinical and Environmental Medicine (Rosenstock L, Cullen MR, eds). 1st ed. Philadelphia:W. B. Saunders Company, 1994;741–742.
28. Toren K, Brisman J, Olin AC, Blanc PD. Asthma on the job: work-related factors in new-onset asthma and in exacerbations of pre-existing asthma. Respir Med 94:529–535 (2000).

THE LATEST WORD ON ENVIRONMENTAL HEALTH

ehis
Environmental Health Information Service

http://ehis.niehs.nih.gov/

VISIT US ON THE WEB TODAY!